

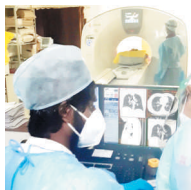J Watumull

# GLOBAL HOSPITAL

& Research Centre

## Newsletter

### Inside this issue



#### Page 4

CT scans break records



#### Page 6

Remembering a donor



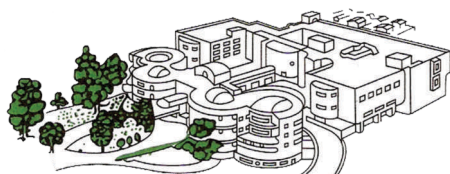
#### Page 7

Plantation drive

*Senior consultant ENT surgeon Dr Sharad Mehta uses the new bronchoscope*

### A new bronchoscope

A rhino laryngo fiberscope with suction capability was procured for the Department of ENT. It is a Hugemed model VL3S bronchoscope with a display screen, adaptor and the associated cables. A big thanks to Lalit Kumar Kataria for contributing to this acquisition.

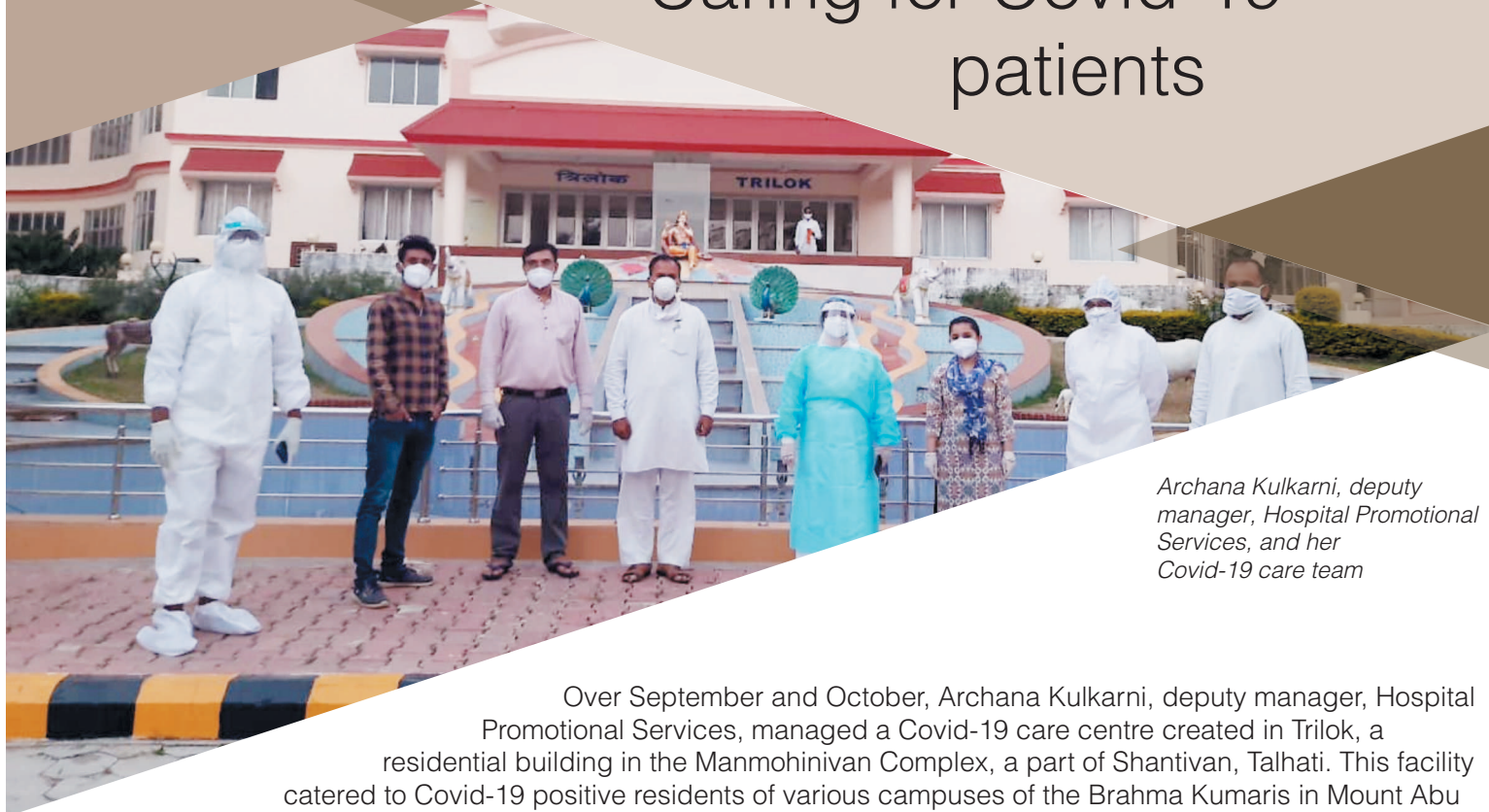


A publication of J Watumull Global Hospital & Research Centre  
[www.ghrc-abu.com](http://www.ghrc-abu.com)

Health Services | Education | Research

OCT 2020  
Volume 141

## Caring for Covid-19 patients



Archana Kulkarni, deputy manager, Hospital Promotional Services, and her Covid-19 care team

Over September and October, Archana Kulkarni, deputy manager, Hospital Promotional Services, managed a Covid-19 care centre created in Trilok, a residential building in the Manmohinivan Complex, a part of Shantivan, Talhati. This facility catered to Covid-19 positive residents of various campuses of the Brahma Kumaris in Mount Abu and Abu Road. Two floors of Trilok were earmarked for male and female wards.

In all, 74 patients were admitted over the first wave of Covid-19. Two patients needed to be referred to a higher centre. Patients needing further investigations such as CT scans (18 referrals) and x-rays (55 referrals) and blood exams (20 referrals) were sent to the Radha Mohan Mehrotra Global Hospital Trauma Centre, Abu Road.

Archana's Covid-19 care team included Dr Pooja Vasoya, resident medical officer; Gopal Sharma, Yogesh Rawal and Suman Nayal, staff nurses; Dharmendra Kumar Singh, quality manager and PRO, Blood Bank & Pathology; Sudhanshu, ambulance driver; Joraram, housekeeping staff; and Ashish, a volunteer.

### Newly joined pathologist Dr Sapna Bhandari shares her experience:

*I joined the Global Hospital & Research Centre trust as a pathologist in August 2020 but my association with this place started when I first visited seven years back. I am not a spiritually inclined person but I was mesmerised by the serenity and calm of the place and the hospitality of the people. When I was looking for opportunities during the lockdown, I preferred Abu over metros. I was surprised to find technical staff like Dharmendra and Sanjeevani whom I had met long back. It boosted my confidence and assured me that I was making no mistake. I was accepted with warmth and respect. I felt at home from the very first day. The management is supportive, other consultants boost my knowledge by healthy discussions. My field of interest is histopathology and cytology and we get quality work not only from surgery and gynaecology but also from ENT, ophthalmology and dentistry. An ophthalmology case has been selected for publication in an indexed journal. Quality work, flexible working hours and a peaceful working environment are the highlights of this place. I am really thankful for this opportunity to work and contribute to the Global Hospital family.*





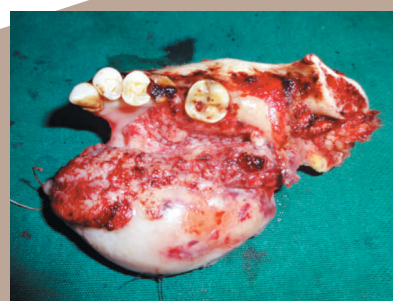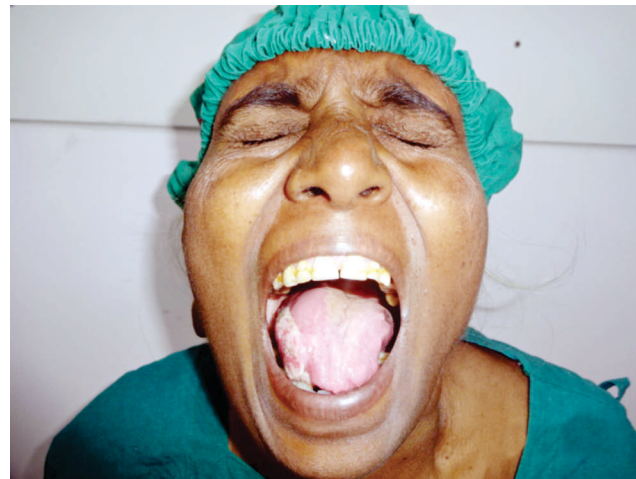## A villager was suspected of having cancer...

Gali Garasia, a 50 year old woman living in Deri, a village in block Abu Road falling in the route of the Community Service Project, presented with suspicious looking ulcers in her mouth. Dr Ashok Dave, clinical associate & coordinator of the Community Service Project, referred her to Dr Sharad Mehta, senior consultant ENT surgeon for further management.

Investigation showed that Gali had cancer of the tongue with secondary spreads in the neck. The cancer had spread from the tongue to the mandible, popularly called the jaw, the largest bone in the human skull which holds the lower teeth in place.

Dr Mehta performed a composite resection, a hemiglossectomy on the right side, an operation to remove part of the tongue and adjacent tissues; and a partial removal of the mandible. Flap reconstruction helped cover the affected area. During the surgery Dr Mehta removed 40 lymph nodes, no cancer was detected in any of these.

Gali was advised to feed herself through a Ryles tube for three months.



## Treating tuberculosis

97 sputum samples were collected from suspect tuberculosis patients between July and September. Of these, 42 were from old patients, the rest were from new cases. 23 samples tested positive, 14 were category 1 cases. 23 patients completed their treatment course during the quarter.

Indra Bhil, 37 years old, is from Redvakala, a village in Abu Road block. Her husband and she are petty farmers. They have four children.

Indra was found to have tuberculosis of chest. She was put on the tuberculosis treatment regimen. She gained 5kg weight over the six months course.

### Donor alert: Bank details for Indian residents

Send your contributions to:

Account number: 4087 020 11000 229

Account holders name: Global Hospital & Research Centre


Bank: Union Bank of India

IFSC Code: UBIN0540871

Let us know your name and address to complete our records.

Email: accghrc@gmail.com

## Record breaking number of CT scans



In the thick of the pandemic, the CT scan at the Radha Mohan Mehrotra Global Hospital Trauma Centre was put to exceptional use since the scan was considered a definitive indicator of the virus, even in cases where the RT PCR test had yielded a doubtful outcome. Consultant radiologist Dr Ananda B was reporting upto 20 scans daily. The x-ray machine was also put to good use.

The number of walk-in patients increased. This was a big positive.

Dialysis sittings also marked a slight increase in view of caring for a few natives of the district who migrated back during the lockdown.

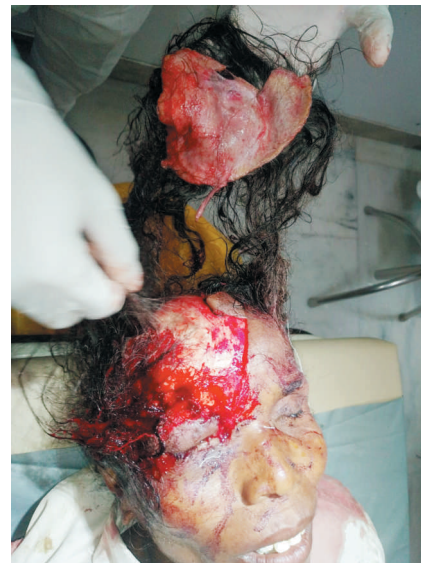ECG, the laboratory and the beds (in that order) were the biggest losers as the number of major operations dropped.

## New joinee

Dr Sapna Bhandari joined as consultant pathologist in August 2020. She is sharing her time with the laboratory at Mount Abu as well. Dr Bhandari has eight years of post qualification experience in SRL Diagnostics, Indore; Apollo BSR Hospital, Bhilai; Kothari Hospital, Bikaner; etc. See page 2 for Dr Bhandari's experience.

## A bear bite case

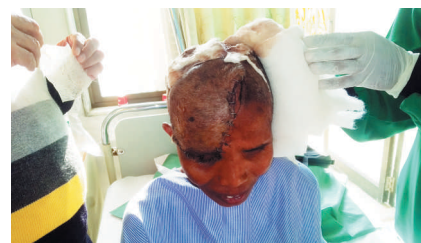Rajkidevi, a 36 year old woman, was working in a field when she was attacked by a bear. She was seriously injured.



*This was Rajkidevi's condition when she was brought in*

Consultant surgeon Dr Anil Bhansali operated on her.

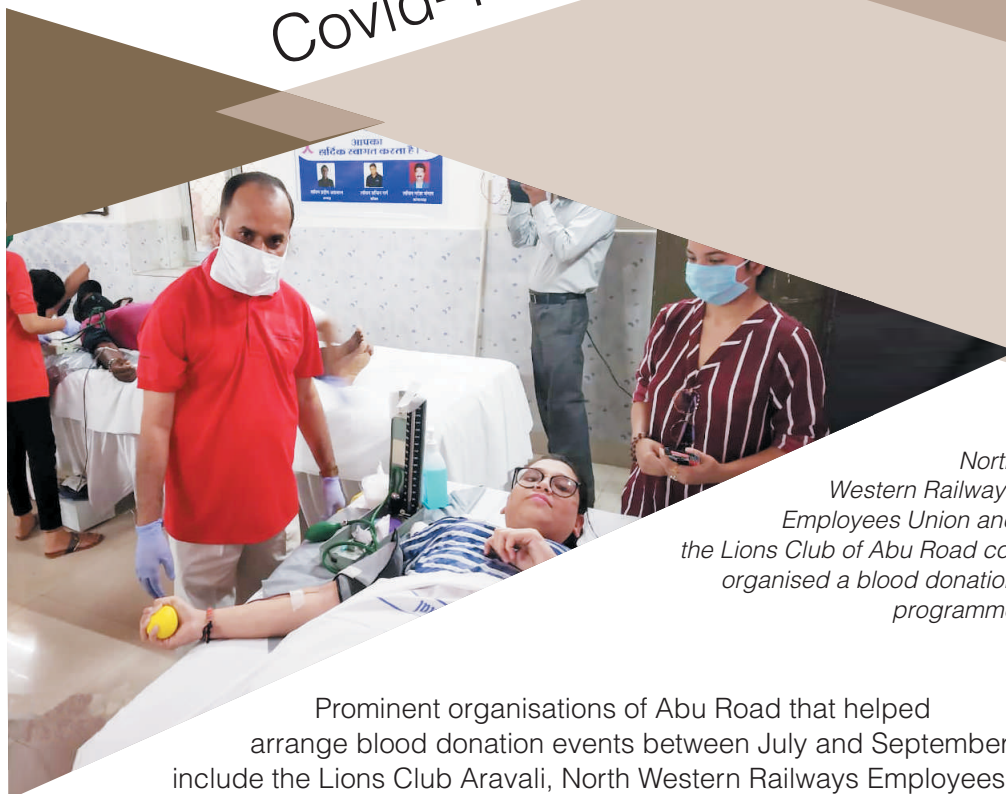Rajkidevi was fortunate to have received support for the treatment from the government under a medical insurance scheme for poor patients.



*Rajkidevi, post-operatively, on the road to recovery*

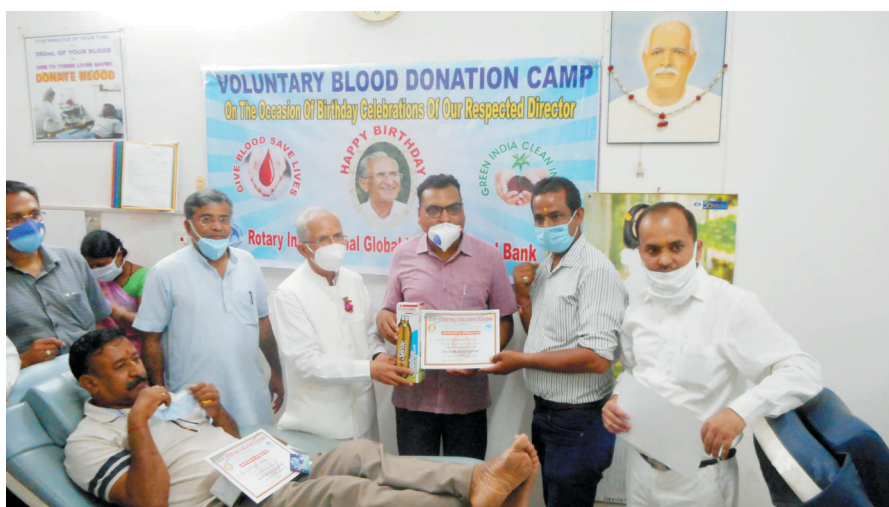

## Collecting blood in Covid-19 times



North Western Railways Employees Union and the Lions Club of Abu Road co-organised a blood donation programme

Prominent organisations of Abu Road that helped arrange blood donation events between July and September include the Lions Club Aravali, North Western Railways Employees Union, Adivasi Yuva Manch, BJP Yuva Morcha and Raktdan Seva Samiti (Reodar). Brother Rajesh (JEN, Anadara) and one school, Adarsh Niketan, also sponsored a programme each. One voluntary blood donation camp was organised on the occasion of the birthday of medical director Dr Partap Midha, on July 26. In all, 596 units of blood were collected.



Medical director Dr Partap Midha presenting certificates to donors after the event on his birthday!

## Quarterly update

Out-patients:

10118

Hospitalised patients:

1043

Operations (major):

92

Operations (minor):

53

Dialysis:

810

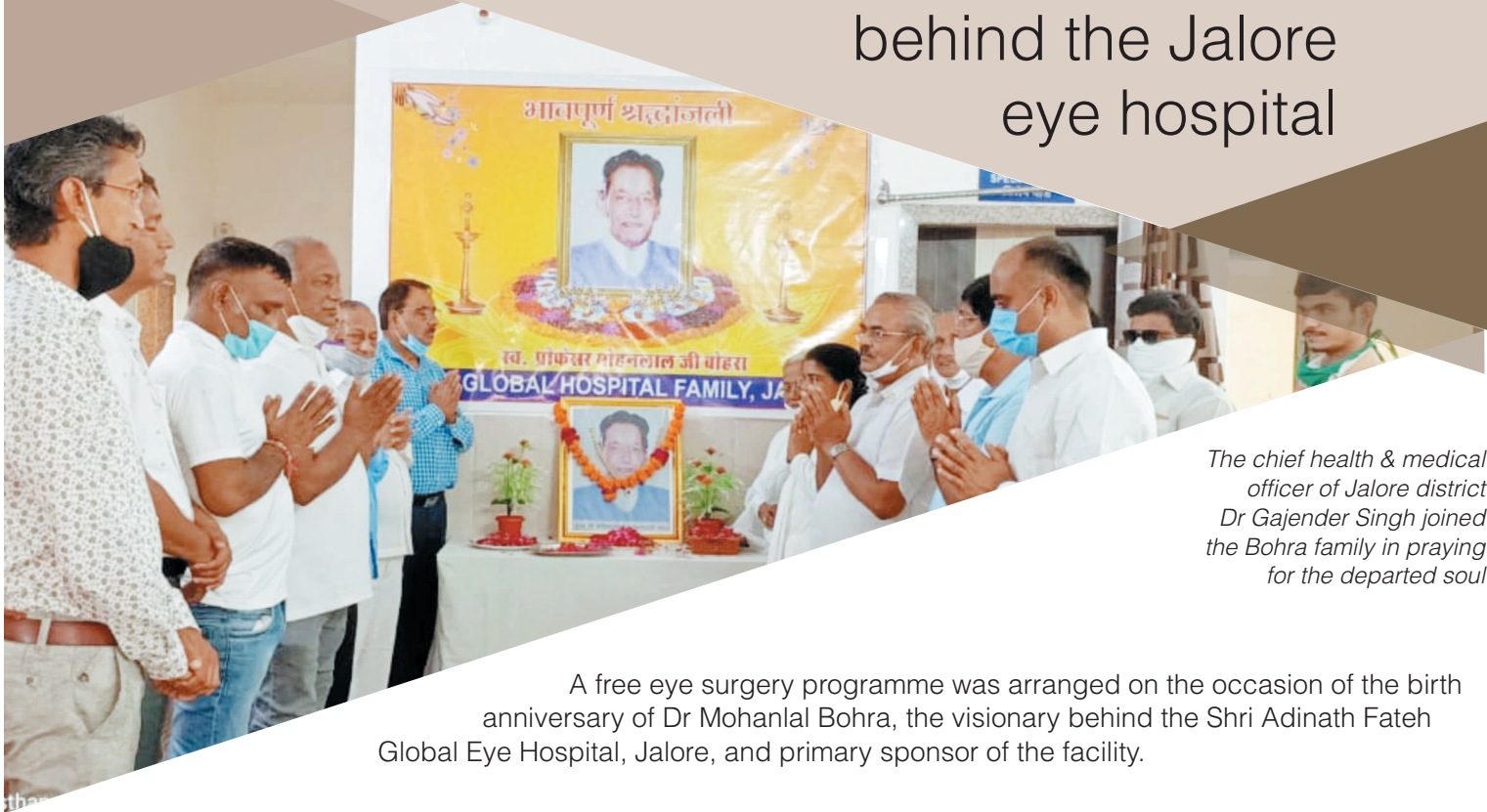## Subscribe

> Write to Sister Archana for a soft copy at [ghrchps@gmail.com](mailto:ghrchps@gmail.com)  
> Request Sister Yashoda for prints, at [ghrcoffice@gmail.com](mailto:ghrcoffice@gmail.com)

## Donate

Global Hospital & Research Centre offers section 80G (50% exemption) tax exemptions on donations. State your address and PAN when making a donation.

## Tribute to the visionary behind the Jalore eye hospital



*The chief health & medical  
officer of Jalore district  
Dr Gajender Singh joined  
the Bohra family in praying  
for the departed soul*

A free eye surgery programme was arranged on the occasion of the birth anniversary of Dr Mohanlal Bohra, the visionary behind the Shri Adinath Fateh Global Eye Hospital, Jalore, and primary sponsor of the facility.

## Budding optometrists

Seventeen students completed the diploma in ophthalmic technicians with flying colours. Despite the pandemic, they insisted on celebrating on September 24!

## Academic achievements

Dr Anshuman Pattnaik and Dr Poulami Pal, DNB Ophthalmology students at the Global Hospital Institute of Ophthalmology successfully submitted their first year thesis to the Scientific Research Committee of the institute.

Dr Pattnaik's study focused on central corneal thickness changes following 6mm MSICS using intratunnel phacofracture technique. Dr Pal studied the epidemiological characteristics, predisposing risk factors and etiologic diagnosis of infective keratitis in South Western Rajasthan (hospital based study).

## Skill development

Global not-for-profit Orbis sponsored three staff members for professional development courses. Orbis gives communities across the world access to quality eye care, transforming lives and restoring vision for those who need it most.

Optometrist Beena Chandrawanshi attended the India FEH Remote Training Course in Biomedical Engineering, DOT student Twinkle Choudhary attended the India FEH Remote Training Course in Ophthalmic Nursing, and DNB Ophthalmology resident Dr Nimesh Purohit attended the India FEH Remote Training Course in medical retina.



## Nursing webinar attended by hundreds



The Clinical Nursing Research Society, headquartered at the Saroj Lalji Mehrotra Global Nursing College, arranged a webinar on the National Educational Policy 2020, its impact on nursing, on September 11. The panelists included Major General Elizabeth John, former additional director general of military nursing, Indian Army, Dr Suresh Sharma, principal of the college of nursing, AIIMS, Jodhpur, and Shreedevi Balachandran, lecturer, Sultan Qaboos University, Muscat. More than 600 nursing professionals attended the webinar. And so did our students!

## EVENTS

### Plantation drive

Rajat Rawat, the manager of the State Bank of India branch in Abu Road unfurled the tricolour and led an on campus plantation drive on Independence Day, August 15.



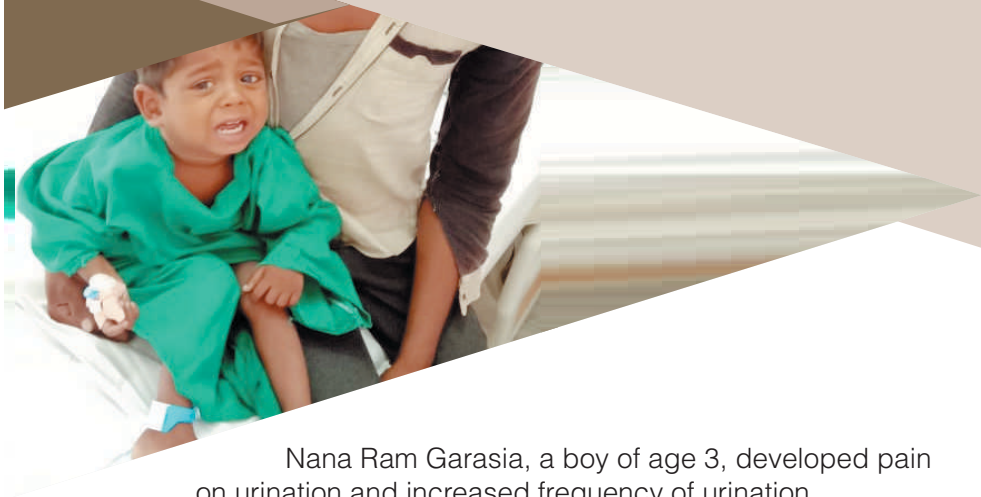## Faculty training

Three faculty members, Banupriya, Sudhanjali Behra, and Nidhisha Pillai attended one week training on midwifery, a virtual capacity building programme organised by the Indian Nursing Council, Delhi, from September 30 to October 7.



The creation of an underground water tank and channel has helped harvest rainwater, which is now used to water plants. The campus looks much greener as a result.

## A case of vesical calculus



Nana Ram Garasia, a boy of age 3, developed pain on urination and increased frequency of urination.

When the boy showed no signs of improvement in a fortnight, his father, Sena Ram Garasia, brought him to Global Hospital.

Dr Tejal Bhoy performed an open cystolithotomy on the child on July 9.

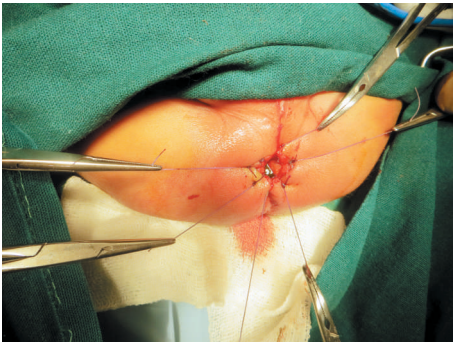
Nana Ram did well post-operatively. His urine culture report showed that he had a bacterial infection. So, he was prescribed more antibiotics as per the culture sensitivity report. By the time he was discharged, Nana Ram was stable and passing clear urine.

Nana Ram's family hails from Siawa, an adopted village of the Village Outreach Programme. Therefore, he was treated for no charges.

## A case of imperforated anus

A male baby was found to have a congenital ano-rectal malformation. He had no perforation of the anus, and hence, he was suffering from abdominal distension. His father rushed him to Global Hospital. The boy was barely a day old.

Dr Dilip Kothari performed an anoplasty on the baby to create a passage for stool to pass through.



## Tuberculosis statistics

patients screened

23

patients tested positive

14

on treatment

8

referred

6

## VOP update

patients in the field

2516

walk-ins

368

admissions

23